

# Erchonia Laser Therapy in the Treatment of Onychomycosis

Robert Sullivan<sup>1</sup> and Deirdre O'Flynn<sup>2</sup>

<sup>1</sup>Clinical Director of Midleton Foot Clinic, Midleton, Ireland

<sup>2</sup>Deirdre O'Flynn Senior Associate, Midleton Foot Clinic

## A preliminary report on an ongoing clinical trial

### Abstract

This is the preliminary report of an ongoing clinical trial in laser therapy using the Erchonia Laser for the treatment of onychomycosis. The study has to date been carried out on 320 patients both male and female with an average age of 40. There is a further 400 patients awaiting treatment to conclude this study. The laser treatment consists of 4 treatments at weekly interval using the Lunula Laser manufactured by Erchonia. This is a laser that combines two different wavelengths of laser light - one at 405 nm for direct fungicidal activity and one at 635 nm to stimulate a natural immune response - to provide effective clearing of the nail bed; it is claimed, within three months. Unlike other lasers used for the treatment of this condition, the Lunula laser is reported to cause no pain to the patient treated and no temperature change to the area exposed to the lights. This is an eighteen month study and is ongoing at this time. The treatment target is eight hundred patients. The follow up intervals are twelve weeks post final laser, twenty four week post final laser, fifty two weeks post final laser and finally at seventy six weeks post laser. Usual studies of this type normally conclude in fifty two weeks or less, however, it is the aim of the researchers to observe the nail up to seventy six weeks to ascertain the efficacy of the treatment. In the treatment to date there has been 36 reports of side effects and the majority 93% of patients are happy with the treatment. It is the primary aim of this study to present laser as an effective treatment for onychomycosis with a good evidence base.

**Key words:** onychomycosis, fungal nail infection, Lunula Laser,

### Introduction

Onychomycosis is a persistent nail infection of the nail bed, the nail matrix and or the nail plate, statistically it is the most common nail disorder in adults affecting up to 50% of patients presenting with nail disorders (Zaias et al 1996, Schlefman 1999, Ghannoum et al 2000). Fungal skin infections account for 33% of all skin infections (Zaias et al 1996,

Schlefman 1999). Onychomycosis is caused by dermatophytes that colonise dead skin, nail and hair tissue and nondermatophyte moulds, Candida species rarely form part of this condition (Evans 1998). The most common dermatophytes seen in the mycology of onychomycosis are Trichophyton rubrum and Trichophyton mentagrophytes, Trichophyton rubrum is responsible for approximately 90% of all presentations (Zaias et al 1996, Schlefman 1999). The over all prevalence of onychomycosis in the general population ranges from 2 to 14%. The risk of infection increases with age and 15 to 20% of the population aged between 40 and 70, 32% of those between 60 and 70 and 48% of those over 70 (Schlefman 1999). Evidence suggests that the instance of onychomycosis in the population is on the rise (Schlefman 1999, Ghannoum et al 2000). There are several conditions that present visually in the same way as onychomycosis including lichen planus, nail trauma, atopic dermatitis and psoriasis.

There are many treatment options for onychomycosis; these include systemic antifungal agents, topical antifungal agents, mechanical debridement, chemical debridement, combinations of these treatments and palliative approaches. The treatment choice is dependent on the practitioners training, experience and other available modalities and interventions as well as cost (Gupta et al 2003)

The treatment of advanced onychomycosis is expensive due to the input needed from the clinician and is subject to high failure rates. Antimycotics prescribed for the treatment of onychomycosis are usually delivered over several months and have cure rates of 40 - 80%, Terbinafine, Fluconazole and Intraconazole are among the more frequently used drugs (Gupta et al 1998, De Doncker et al 1996). These drugs however are associated with a number of common side effects such as headache, rash, gastrointestinal and endocrine disturbances (liver) (Gupta et al 1998, Scher 1999). The usual course of drug therapy is for three months unless a pulse

dose is used. Patients have the inconvenience of frequent blood tests during drug therapy. Topical antifungal products are widely promoted on the television and other media, these products are available direct to the public without a prescription, they are safe to use and relatively cheap, these topical products are seldom effective (Ciclopirox 2000).

Lasers have been used in medical settings for a considerable time. Lasers used however in the treatment of onychomycosis have not, nor have they undergone any rigorous examination. There has to date been no significant clinical trial carried out on a large demographic to support the claims made by manufacturers of laser devices claiming market advantage with their products. It is the intention of this study to produce good quality information from research that will support or deny the use of laser in the treatment of onychomycosis to inform best practice.

This study is presented using simple statistics expressed as a percentage, the figures shown are as the authors and other clinicians understand. P values etc will be calculated and extensive statistical analysis made at the end of this study. But in this the primary report the authors have kept it simple and basted their finding in clinical evidence based practice.

### Methods

This clinical study relies on all subjects having a positive mycology, therefore there is no need for a control group as all patients received active laser. 320 patients or 2320 toes were subject to laser irradiation at 405nm and 635nm for twelve minutes at weekly intervals for four weeks.

### Inclusion criteria

Participation in this study is reliant on the following:-

- onychomycosis present in at least one great toenail.
- Disease involvement in the great toenail(s) with onychomycosis of at least 10%.

- Spikes of disease extending to the nail matrix in the affected great toenail(s).
- Proximal subungual onychomycosis.
- Distal subungual onychomycosis.
- White superficial onychomycosis.
- Patient is willing and able to refrain from using other (non-study) treatments (traditional or alternative) for his or her toenail onychomycosis throughout study participation.
- Patient has not used other treatments for at least 6 months prior to participation in the study.
- Patient is willing and able to refrain from the nail cosmetics such as clear and/or colour nail lacquers throughout study.
- Male or female. 18 years of age or older.

A copy of the study protocols is available on request.

### Exclusion criteria

Patients who have used oral antifungal medicines within 3 months prior to the administration of the first laser treatment are excluded from this study as are patients who are unable to abstain from the use of nail cosmetics. Other exclusions are nevus subungual formation, psoriasis of the nail plate, atopic dermatitis and lichen planus.

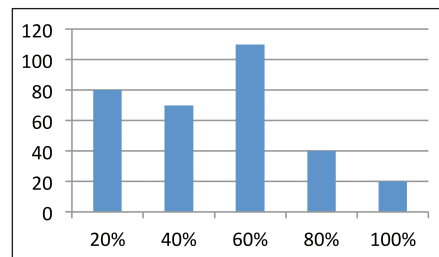
### Treatment procedure

This treatment has two principle aims, 1.) to restore the affected nails to health within the 18 month course of this study, and 2.), to eradicate the fungus from the nail and related area within the four week treatment protocol.

As this is a positive mycology study only patients who test positive for onychomycosis and meet the inclusion criteria are offered treatment. Samples were collected and cultured in the normal way. Patients were treated in groups dependent on the percentage nail inclusion. The graph shows the average percentage amount of total nail infected at

the time of treatment in the 320 patients. All patients were given a diary to fill in every week noting any adverse response to treatment along with any visual changes to the nail. No support products were given and all subjects had to refrain from using any nail cosmetics for the duration of the laser active stage in the study.

All patients were treated as outlined below at each of their four visits.



Graph showing % nail inclusion

1. The foot to be treated was cleansed using a clinell wipe.
2. Nails were clipped and reduced using a bur where necessary.
3. The foot was cleansed to remove any debris and dust.
4. The forefoot was photographed using a high resolution digital camera. These photos were taken from a fixed position that was repeatable throughout the study. Measurements were taken from the pictures by an independent lab using digital measures.

It is important to note that no chemicals were used to pre soften thickened nails as the researchers wanted to remove any possibility of interference from outside sources.

This is a four week protocol where the laser is administered on the same day each week for 12 minutes. All laser units are programmed to deliver constant therapy for this time and then turn off.

After the pre-treatment was complete the laser therapy was administered using the LanulaLaser™ (Erchonia FX-405™). This is a double-headed laser with a dual-diode emitting a light wavelength of 635 nm and 405 nm covering both the

ultraviolet and infrared light spectrums. The device is mains powered and stands on the floor. The treatment area of the unit is aseptically cleaned after each patient is treated. The diagram shows the, 1.) laser diodes, 2.) the magnetic catch for closing the unit, 3.) the heel plate which is also the door to the unit and 4.) the aperture into which the forefoot sits for the 12 minute treatment.

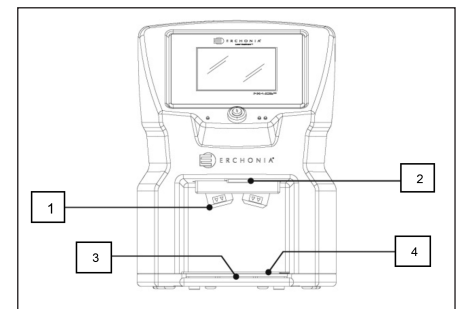


Diagram showing the laser unit used

Unlike other laser applications used for the treatment of onychomycosis no reports of any pain were made by any of the 320 patients (2320 toes) which have currently been treated.

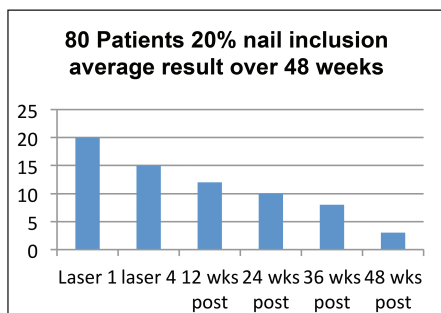
### Treatment reviews points

It is important to remember that this is an 18 month study. 18 months was chosen in order to evaluate the long term effects of the treatments and to chart any recurrence rate. It should be further noted that a recurrence after a clear nail is presented is not evidence of treatment failure as environmental factors must be taken into account. All patients on this study are issued with a "Maintaining Your Foot Health" leaflet.

Follow up measurements were taken at 12 week post final (fourth) laser as well as at 24, 36 (samples taken for mycology), 48, 52, 64 and 76 weeks. A patient is discharged from the study once a clear nail is presented and maintained for 12 weeks.

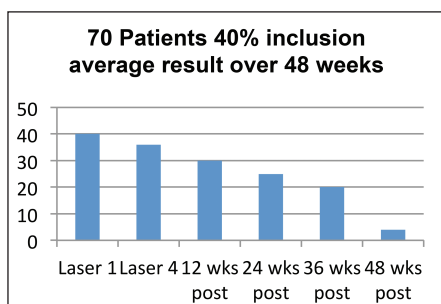
### Interim results

The following graphs represent the findings to date and show the amount of remaining infected nail at the time of publication:-



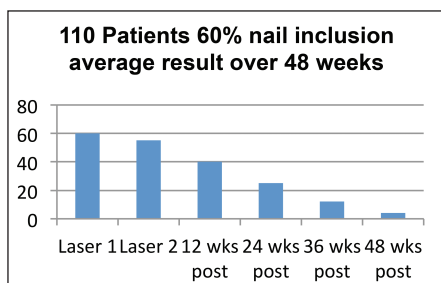
Graph 1

Of the 80 patients shown in this graph 72 or 90% were discharged by week 48 as they presented with clear nails which remained clear for 12 weeks. None of these patients required additional treatments at this time and it is expected that by week 52 all will have been discharged.



Graph 2

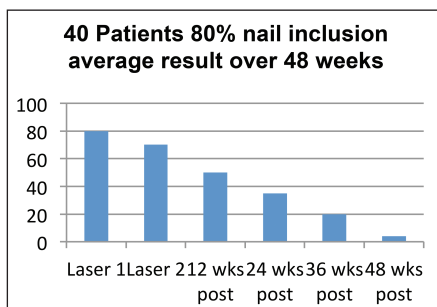
The above graph shows the average remaining infected nail at 48 week. 61 or just over 87% of patients were discharged from the study due to clear presentation at 48 weeks and 2 were recommended to have further treatments.



Graph 3

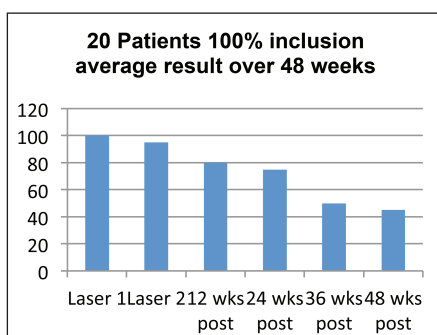
At week 48, 88 patients, or just over 80% were discharged from the study as they presented with clear nails. 5 patients were recommended to have further treatments.

Of the 40 patients 18 were discharged



Graph 4

from the study by week 48 as they presented with clear nails, this represents a 45% success rate with 80% nail inclusion



Graph 5

1 was recommended further treatment.

No patients were discharged from this group and all patients have been recommended further treatments as they have all seemed to reach a plateau where the nail has no significant growth from week 36 to week 48. The average growth rate in this cohort is 51% over 36 weeks. Blood and tissue analysis was carried out on samples taken from the nail matrix and it was noted that there was a lack of fat cells at the matrix. Further investigation is ongoing.

### Findings from patient's diary's

Adverse reactions from the notes of the 320 participants involved to date

- Tingling sensation during treatment was reported by 29 patients, all however said that this was slight and the common consent was that it felt like a vibration in the forefoot.
- 1 patient reported headache every time the laser was activated. Glasses were given for the frequencies used but the pain still persisted.

- 4 patients felt numbness to the forefoot
- 2 patients related that they had diarrhoea that they felt was a direct result of the treatment.

The total of adverse events was 36 of the patients involved in this study 201 were women and 119 were men. 72 patients reported using nail cosmetics during the treatment stage of the study.

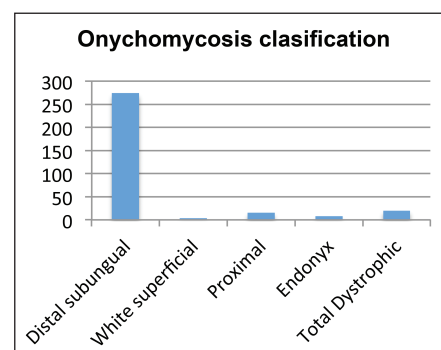
### Types of Onychomycosis

Onychomycosis may be classified into several types: distal subungual, white superficial, proximal subungual, endonyx, and total dystrophic.

Distal subungual onychomycosis, was the most common type seen in this study today, this involves the nail bed and subsequently the nail plate. White superficial onychomycosis was seen as superficial white patches with distinct edges on the surface of the nail plate. Proximal subungual onychomycosis is a result of the fungal organism entering via the cuticle and the ventral aspect of the proximal nail fold. In endonyx onychomycosis, fungal organisms invade the nail plate without resulting nail bed hyperkeratosis, onycholysis, or nail bed inflammatory changes. In total dystrophic onychomycosis, complete dystrophy of the nail plate occurs; these changes may be primary or secondary.

### Data to date in plain English

All of the above graphs and results are predicated on four laser treatments over 4 weeks with these results processed as per the finding up to and including week 48. Further results will be published at the end of the study for all timelines as per the protocol.





Graph 1 shows the progression of the 20% infected nail cohort. There were 80 patients in this group, by week 48, 72 of these patients had been discharged and therefore one can conclude that over 48 weeks with four laser applications a success rate of 90% was achieved.

Graph 2 is the results of the second treatment cohort with 40% nail inclusion. These patients had at least 21% inclusion and show a success rate of 87% with a four week treatment protocol.

Graph 3 is the result drawn from the third cohort with 60% nail inclusion. All of these patients had at least 41% inclusion and show a success rate of 80%, again with a four laser application.

Graph 4 shows the results of the fourth cohort with 80% nail inclusion. All of these patients had at least 61% inclusion and show a success rate of 45%, with the standard delivery protocol applied.

Graph 5 is the result of the fifth cohort with 100% nail inclusion. No patient has been discharged from this cohort at this time but all show good growth, the average being 51%

From the above interim results from this study it is possible to say that this type of cold laser (Lunula Laser manufactured by Erchonia) with a dual light frequency is 84.25% effective over 48 week on onychomycosis for nails up to 80% effected with the condition, and 51% affective on nails that are totally included and on endonyx or dystrophic.

## Discussion

Dermatophytes cause infections of the skin, hair and nails due to their ability to obtain nutrients from keratinised material. The organisms colonize the keratin tissues and inflammation is caused by host response to metabolic by-products. They are usually restricted to the nonliving cornified layer of the epidermis because of their inability to penetrate viable tissue of an immunocompetent host. Invasion does elicit a host response ranging from mild to severe. Acid protenases, elastase, keratinase and other proteinases reportedly act as virulence factors (Rosenberg and Gallin 1999).

Dermatophytes are transmitted by direct contact with infected host (human or animal) or by direct or indirect contact with infected exfoliated skin or hair in clothing, combs, hair brushes, theatre seats, caps, furniture, bed linens, shoes, socks, towels, hotel rugs, sauna, bathhouse, and locker room floors (Ajello and Getz 1954). Depending on the species the organism may be viable in the environment for up to 15 months. There is an increased susceptibility to infection when there is a pre-existing injury to the skin such as scars, burns, excessive temperature and humidity.

Increasingly Onychomycosis is being viewed as a more cosmetic problem as people become ever more conscious of their appearance. Fungi from the nails may happen before secondary bacterial infections such as cellulitis, idiopathic reactions and chronic urticarial. Infected toenails may act as a reservoir for fungi, facilitations their transmission to other parts of the body and potentially to other people.

Clinical diagnosis of Onychomycosis is based on physical examination, microscopy and culture of nail specimens. Factors such as diabetes, hyperhidrosis, nail trauma, poor peripheral circulation; can contribute to the condition. Differential diagnosis for onychomycosis, as mentioned earlier, should be considered so as to allow the clinician to choose the most appropriate treatment.

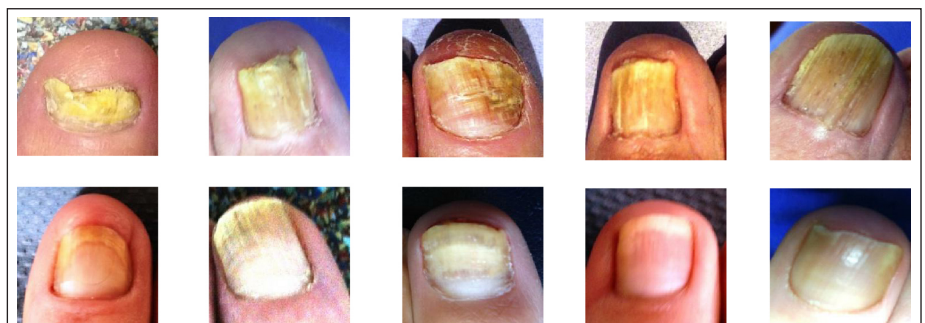It has been found to date, in this study, that 4 treatments for nails up to 60% inclusion has a satisfactory outcome and that nails with over 60% benefit from further pain free treatments. The authors

of this study would agree with a recent comment made by Kerry Zang, one of the lead developers of this laser system, Unlike other treatment modalities, such as systemic anti-fungal agents or repeated Class IV lasers, the Lunula cold laser system can be utilized as many times as necessary to resolve the problem and can be utilized without fear of any side effects or adverse reactions (Zang 2013).

## Conclusion

Lunula laser has performed consistently throughout this study. This study is now approximately half way through and some end point data (18 months post last laser) is now being generated and this is looking very promising. The authors of this study report agree with Kerry Zany when he says, I believe that the Lunula laser system stimulates the production of peroxytrite which interacts with the lipid portions of the cell membrane as well as DNA and other protein components of the invading micro-organisms which is cytotoxic to and inactivates the mycosis. The patients general medical condition influences the rate of nail growth and the effects the risks for re-infection. Depending on the patients general condition will determine the number of treatments necessary to cytotoxic to the mycosis present.

References and full study protocols are available on request from the principal author [robertsullivan01@gmail.com](mailto:robertsullivan01@gmail.com)



The above plates show the before treatment (top) and the below plates show 48 post treatments